

Interactive CardioVascular and Thoracic Surgery

Our experience of popliteal vein aneurysm

Roberto Gabrielli, Silvio Vitale, Alessandro Costanzo and Alessandro Carra
Interact CardioVasc Thorac Surg 2010;11:835-837; originally published online Sep 29,
2010;
DOI: 10.1510/icvts.2010.248823

The online version of this article, along with updated information and services, is
located on the World Wide Web at:

<http://icvts.ctsnetjournals.org/cgi/content/full/11/6/835>

Interactive Cardiovascular and Thoracic Surgery is the official journal of the European Association for Cardio-thoracic Surgery (EACTS) and the European Society for Cardiovascular Surgery (ESCVS). Copyright © 2010 by European Association for Cardio-thoracic Surgery. Print ISSN: 1569-9293.

Case report - Venous

Our experience of popliteal vein aneurysm

Roberto Gabrielli*, Silvio Vitale, Alessandro Costanzo, Alessandro Carra

Department of Vascular Surgery, 'Policlinico Casilino' of Rome, Rome, Italy

Received 16 July 2010; received in revised form 9 September 2010; accepted 11 September 2010

Abstract

Popliteal venous aneurysms (PVA) are rare and in most cases the first sign of their presence is a pulmonary embolus or other thromboembolic events. We report four cases of PVA, in two of these the first sign of their presence was an acute pulmonary embolism; in two remaining cases the diagnosis was fortuitous. Accurate evaluation of venous system of lower limb by duplex scan is important in all cases of pulmonary embolism, the anticoagulation may be ineffective in preventing pulmonary embolism and the surgical repair is the mainstay of therapy of this pathology because it is safe and effective.

© 2010 Published by European Association for Cardio-Thoracic Surgery. All rights reserved.

Keywords: Popliteal vein aneurysm; Pulmonary emboli; Tangential venorrhaphy

1. Introduction

Primary venous aneurysms are rare and in most cases the first sign of their presence is a pulmonary embolus and other thromboembolic events.

Venous aneurysms are in most cases of little clinical significance, but they can be a form of a potentially life-threatening disease such as deep-vein thrombosis, pulmonary embolism and death.

We describe four cases of popliteal venous aneurysms (PVA), to underline the importance of accurate diagnosis and surgical repair in preventing embolic events.

2. Case reports

2.1. Case 1

A 37-year-old man presented with acute shortness of breath. The ventilation-perfusion scan revealed pulmonary emboli. Venous duplex imaging demonstrated the presence of a thrombosed saccular PVA 3.2×3.6 cm, with deep vein patency. The circulating β_2 glycoprotein, dependent anti-cardiolipin antibodies (ACA) was presented. There was no history of previous venous thrombosis or trauma. The anticoagulation therapy was started, and a temporary inferior vena cava filter (ICV filter) (Celect™) was inserted. Tangential aneurysmectomy and lateral venorrhaphy were performed (Fig. 1).

2.2. Case 2

A 67-year-old man presented with acute shortness of breath not associated with pleuritic chest pain or hemo-

ptysis. The ventilation-perfusion scan demonstrated multiple segmental abnormalities highly suggestive of pulmonary embolism, venous duplex imaging demonstrated the presence of a thrombosed fusiform PVA 2.9×3.6 cm, he was placed on anticoagulant therapy. Tests for thrombophilia were negative. Two hours later he experienced pleuritic chest, tachycardia and right ventricular failure with presence of cardiac biomarkers suggested of a severe hemodynamic instability. The patient was treated with 100 mg tissue-type plasminogen activator (rtPA) peripherally over 2 h with a marked clinical improvement.

A temporary ICV filter (Bard Recovery Cone® Removal System) was placed and a resection of venous aneurysm with interposition autologous vein graft was performed. The histopathologic examination revealed an aneurysm venous wall with thickened, fibrotic, moderately cellular intima adjacent to a densely fibrotic adventitia.

2.3. Case 3

A 39-year-old man presented an asymptomatic mass in the left popliteal fossa. Imaging of the duplex scan revealed a 3.2 cm saccular PVA. On physical examination a soft, non-pulsatile and compressible mass was identified. His medical history was hypertension, diabetes and lung cancer treated with chemotherapy. The patient electively underwent tangential aneurysmectomy and lateral venorrhaphy. The histopathologic examination revealed an aneurysm venous wall with focal reduplication of the internal elastic lamina.

2.4. Case 4

A 21-year-old male footballer presented left popliteal fossa discomfort, in particular during palpation and usual

*Corresponding author. Via Don Luigi Sturzo 9, Anguillara Sabazia, Rome, Italy. Tel.: +39 339 1654903.

E-mail address: rogado@libero.it (R. Gabrielli).

© 2010 Published by European Association for Cardio-Thoracic Surgery

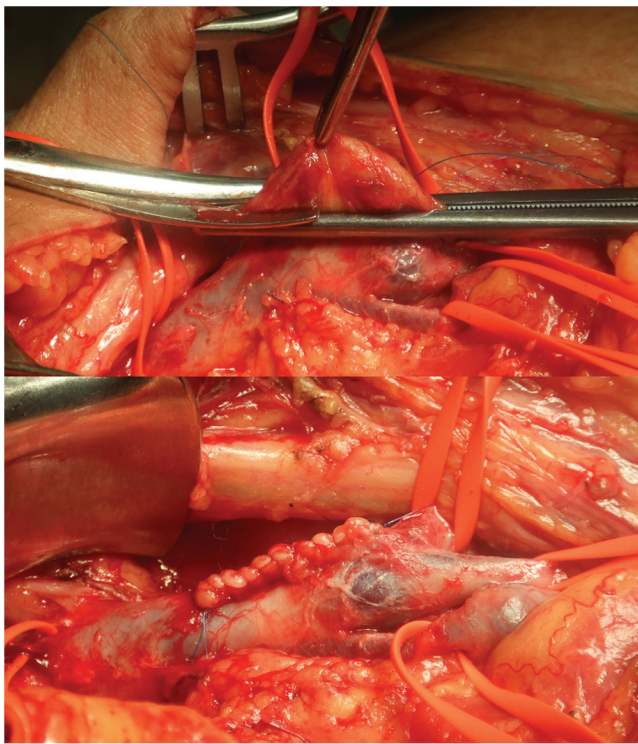


Fig. 1. Intraoperative image showing tangential aneurysmectomy and lateral venorrhaphy.

daily activities. On physical examination a soft and compressible mass was not identified. Color-Doppler ultrasonography was performed to identify the true origins of this lesion. Subsequently, angio-computed tomography (ACT) confirmed a 36×17 mm oval mass in the left popliteal fossa continuous with the popliteal veins (Fig. 2). The popliteal fossa was explored through a posterior approach through an S-shaped incision and the patient underwent tangential aneurysmectomy and lateral venorrhaphy.

All patients had an uneventful recovery, and they were discharged on acenocumarolo therapy for 3–4 months. In the two symptomatic cases the temporary IVC filter was removed after three months discharge.

At a 6–8 month follow-up a duplex scan demonstrated deep venous system patency without symptoms in all cases.

3. Discussion

PVA is uncommon, with approximately 122 cases documented [1, 2]. The first characterization of venous aneurysm as a clinical entity arose in 1915 by Osier during autopsy studies. The first asymptomatic PVA was reported by May and Nissel [3] in 1968. In 1976, Dahl et al. [4] described a symptomatic thrombosed PVA with pulmonary embolism. Asymptomatic incidental detection, local lower extremity symptoms or embolic pulmonary episodes may represent different aspects of the same condition [5].

The pathogenesis of venous aneurysm is not clear, including inflammation, infection, congenital vein wall weakness, mechanical trauma, hemodynamic, and localized degenerative change [6].

On physical examination it positively identified a soft and compressible mass in 26% of the cases [7].

A differential diagnosis of PVA could be the Baker's cyst and tibiofibular cysts.

Venous duplex scan is the diagnostic method of choice to assess the lower limb deep vein aneurysm, and to define the aneurysm size and morphology, however, we recommended the CT-scan or ascending venography before surgical repair, to investigate the assessment of deep vein and to delineate venous anatomy [8].

Venous aneurysm can be defined as a persistent isolated dilatation of twice the normal vein diameter [9] or three times as great.

Pulmonary embolic events were the commonest presentation of venous aneurysm presentation of venous aneurysm, the risk is unpredictable and may be unrelated to the presence or absence of thrombus on imaging studies [8]. According to the literature the anticoagulation therapy may be ineffective in preventing pulmonary embolism, therefore surgical repair is recommended in asymptomatic patients and mandatory in all patients with symptomatic deep vein aneurysm.

We believe that patients with pulmonary emboli with severe hemodynamic instability and venous aneurysm that thrombolytic therapy is important to improve cardiopulmo-

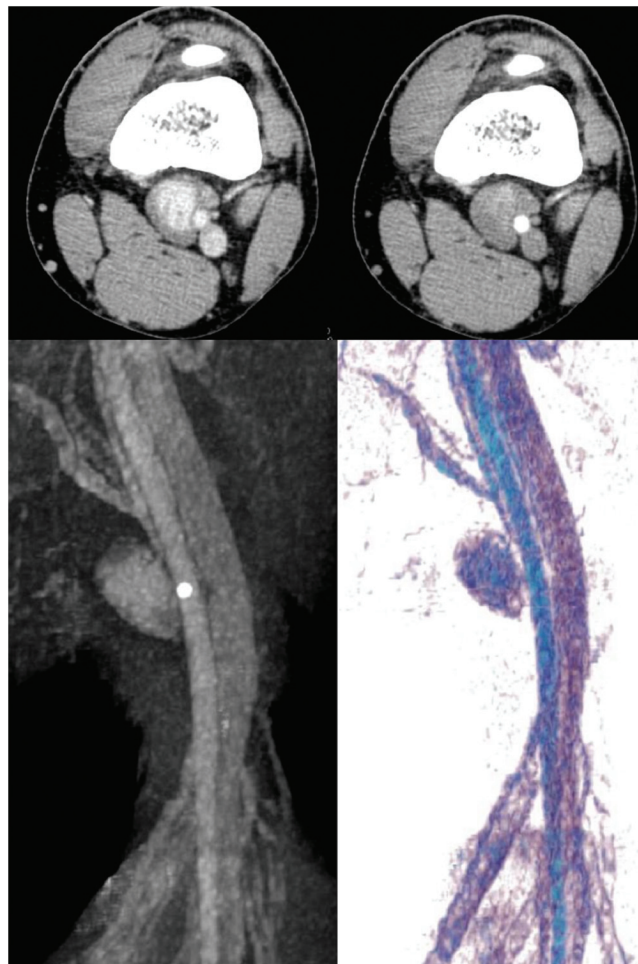


Fig. 2. Angio-computed tomography (ACT) acquisition confirmed a 36×17 mm oval mass in the left popliteal fossa and appeared to be a true venous aneurysm; scan reconstruction using maximal intensity projection and volume rendering technique showing the popliteal venous aneurysm.

nary function and to reduce thrombus in the aneurysm; IVC filter placement is useful before surgical repair to reduce the risk of embolism during the surgical aneurysm repair. Surgical posterior approach is most commonly performed to allow proximal control. Aneurysmectomy and lateral venorrhaphy is available to saccular venous aneurysms, and occasionally can be resected and ligated; in selected patients graft can be placed. Fusiform aneurysms can be treated with resection with end-to-end anastomosis, resection with interposition graft, bypass or ligation of the proximal and distal vein.

After surgical repair we recommend the anticoagulant therapy for three months [7].

To our knowledge anticoagulation may be ineffective in preventing pulmonary embolism during thrombosis of PVA; early patency rates are encouraging, with no reports of recurrent pulmonary embolism following surgical repair, although the long-term results of surgery are unknown, and only cases of recurrence of PVA after lateral tangential aneurysmectomy have been previously reported [10].

4. Conclusion

PVAs are infrequent and potentially life-threatening; early diagnosis is essential to prevent risk of embolism or other major complications.

We underline the importance of accurate evaluation by duplex scan of lower limb venous system in all cases of pulmonary embolism and early surgical repair of PVA because it is safe and effective.

References

- [1] Sessa C, Nicolini P, Perrin M, Farah I, Magne J, Guidicelli H. Management of symptomatic and asymptomatic popliteal venous aneurysms: a retrospective analysis of 25 patients and review of the literature. *J Vasc Surg* 2002;32:912.
- [2] Sigg P, Koella Ch, Stöbe C, Jeanneret CH. Popliteal venous aneurysm, a cause of pulmonary embolism. *Vasa* 2003;32:221–224.
- [3] May R, Nissel R. Aneurysma der Vena poplitea. *Rofo Fortschr Geb Rontgenstr Neuen Bildgeb Verfahr* 1968;108:402–403.
- [4] Dahl JR, Freed TA, Burke MF. Popliteal vein aneurysm with recurrent pulmonary thromboemboli. *J Am Med Assoc* 1976;236:2531–2532.
- [5] Herrera LJ, Davis JW, Livesay JJ. Popliteal vein aneurysm presenting as a popliteal mass. *Tex Heart Inst J* 2006;33:246–248.
- [6] Schatz IJ, Fine G. Venous aneurysms. *N Engl J Med* 1962;266:1310–1312.
- [7] Bergqvist D, Bjorck M, Ljungman C. Popliteal venous aneurysm: a systematic review. *World J Surg* 2006;30:273–279.
- [8] Coffman SW, Leon SM, Gupta SK. Popliteal venous aneurysms: report of an unusual presentation and literature review. *Ann Vasc Surg* 2000;14:286–290.
- [9] MacDevitt DT, Lohr JM, Martin KD, Welling RE, Sampson MG. Bilateral popliteal vein aneurysms. *Ann Vasc Surg* 1993;7:282–286.
- [10] Falls G, Eslami MH. Recurrence of a popliteal venous aneurysm. *J Vasc Surg* 2010;51:458–459.

Our experience of popliteal vein aneurysm

Roberto Gabrielli, Silvio Vitale, Alessandro Costanzo and Alessandro Carra
Interact CardioVasc Thorac Surg 2010;11:835-837; originally published online Sep 29,
2010;

DOI: 10.1510/icvts.2010.248823

This information is current as of November 20, 2010

**Updated Information
& Services**

including high-resolution figures, can be found at:
<http://icvts.ctsnetjournals.org/cgi/content/full/11/6/835>

References

This article cites 10 articles, 1 of which you can access for free at:
<http://icvts.ctsnetjournals.org/cgi/content/full/11/6/835#BIBL>

Permissions & Licensing

Requests to reproducing this article in parts (figures, tables) or in
its entirety should be submitted to: icvts@ejcts.ch

Reprints

For information about ordering reprints, please email:
icvts@ejcts.ch

Interactive CardioVascular and Thoracic Surgery